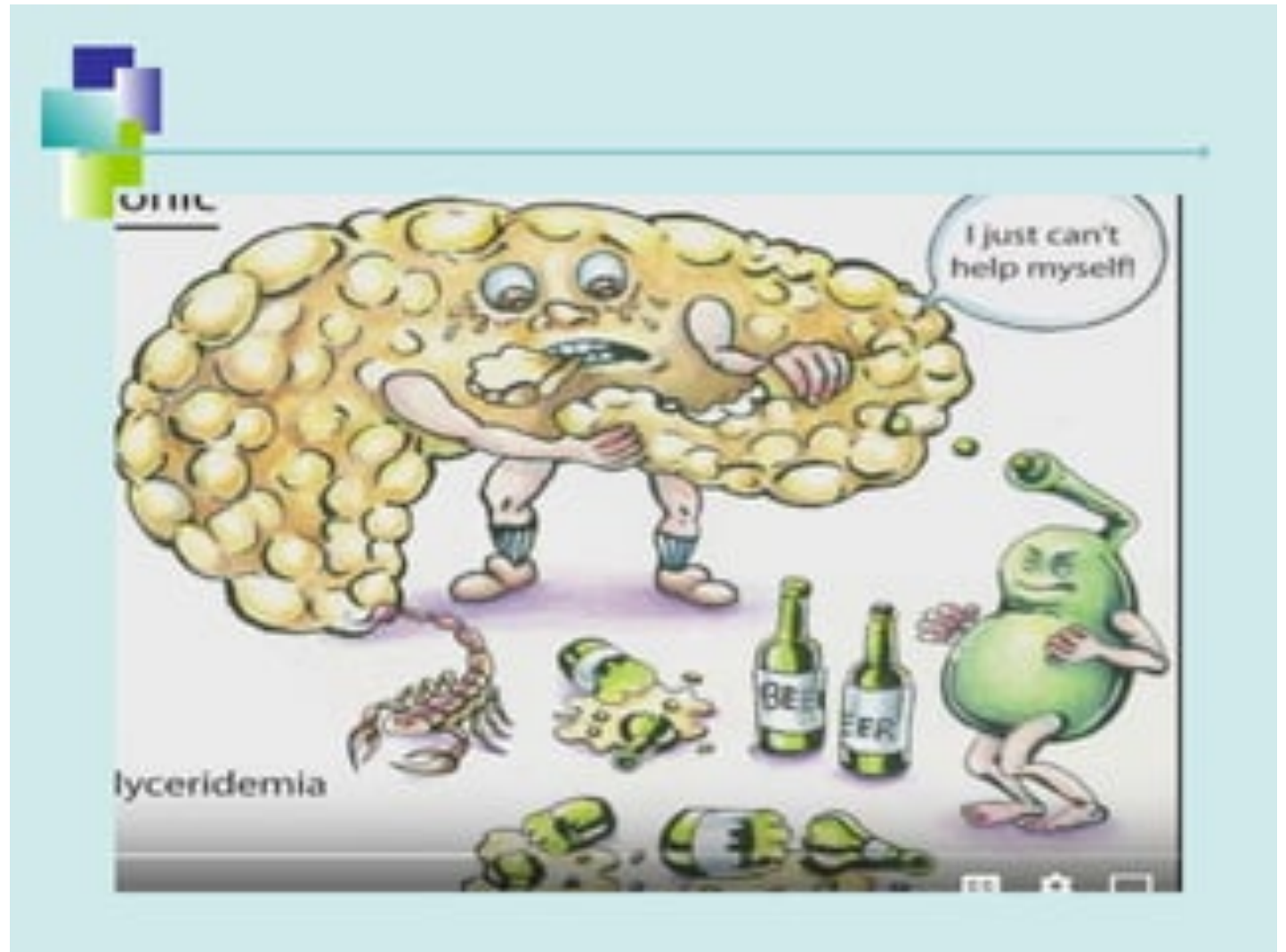
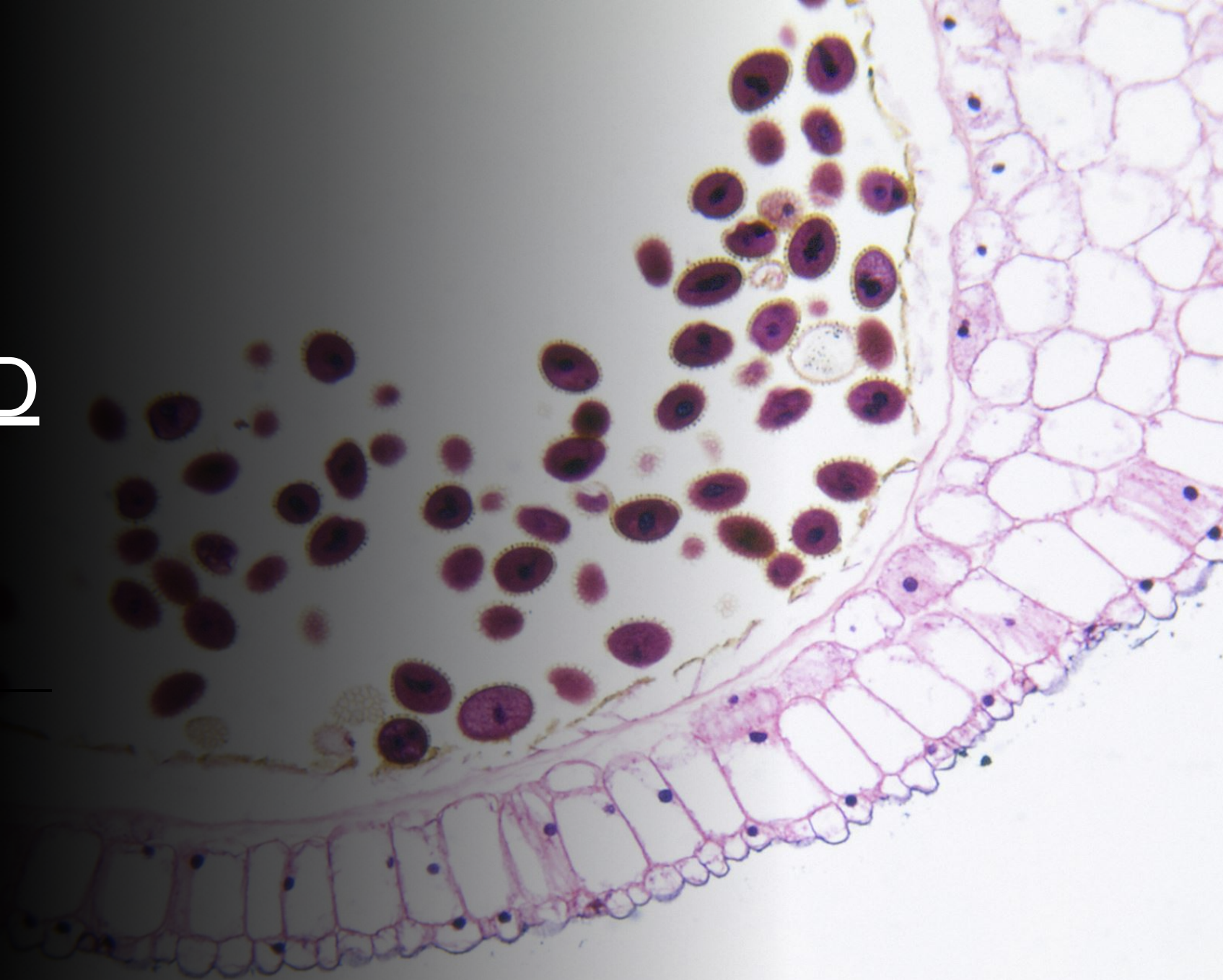


What are we
going to talk
about ?
Any guess!



PANCREAS AND
PANCREATIC
CYSTS





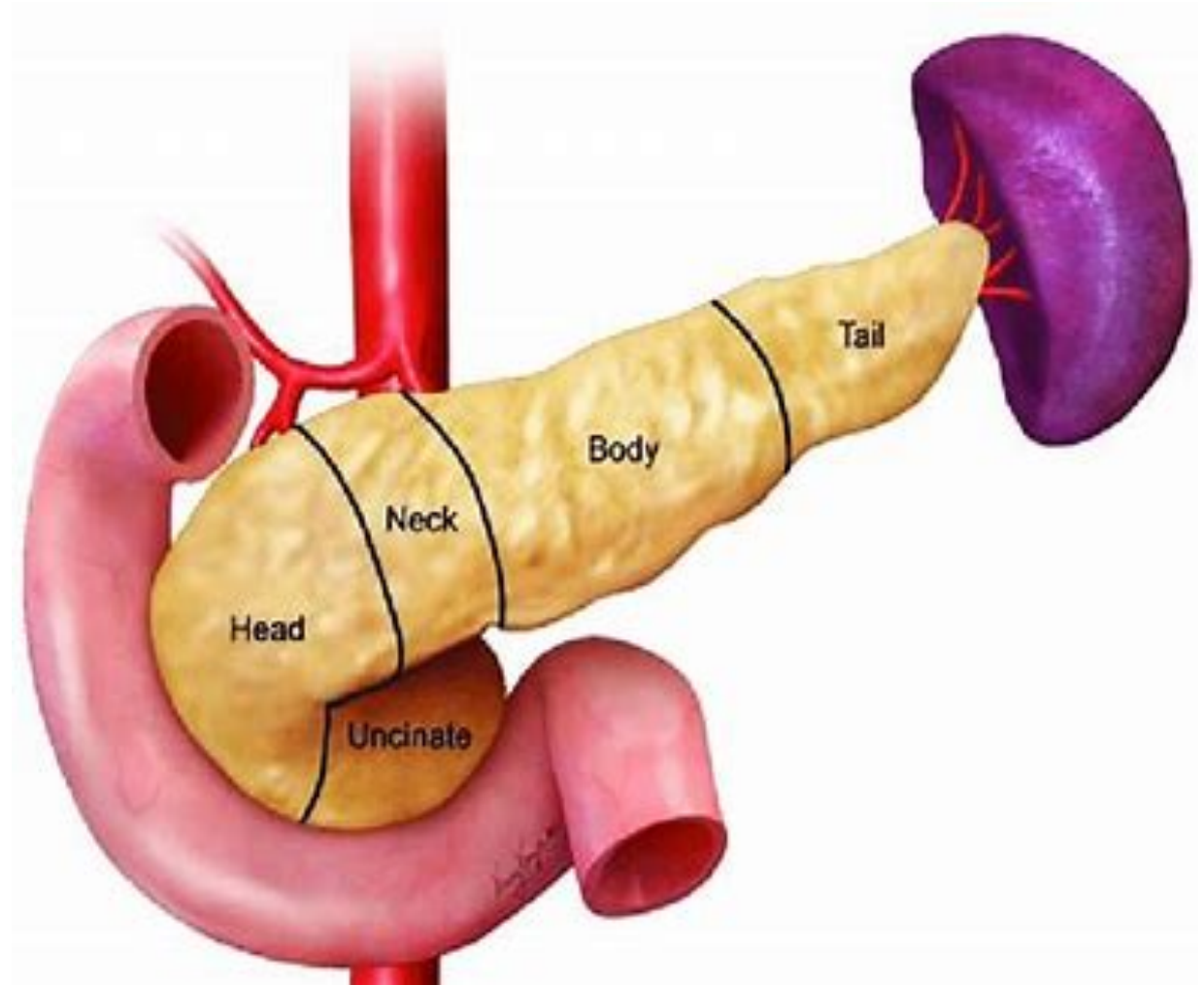
Knowledge Check

[Survey | Poll Everywhere](#)



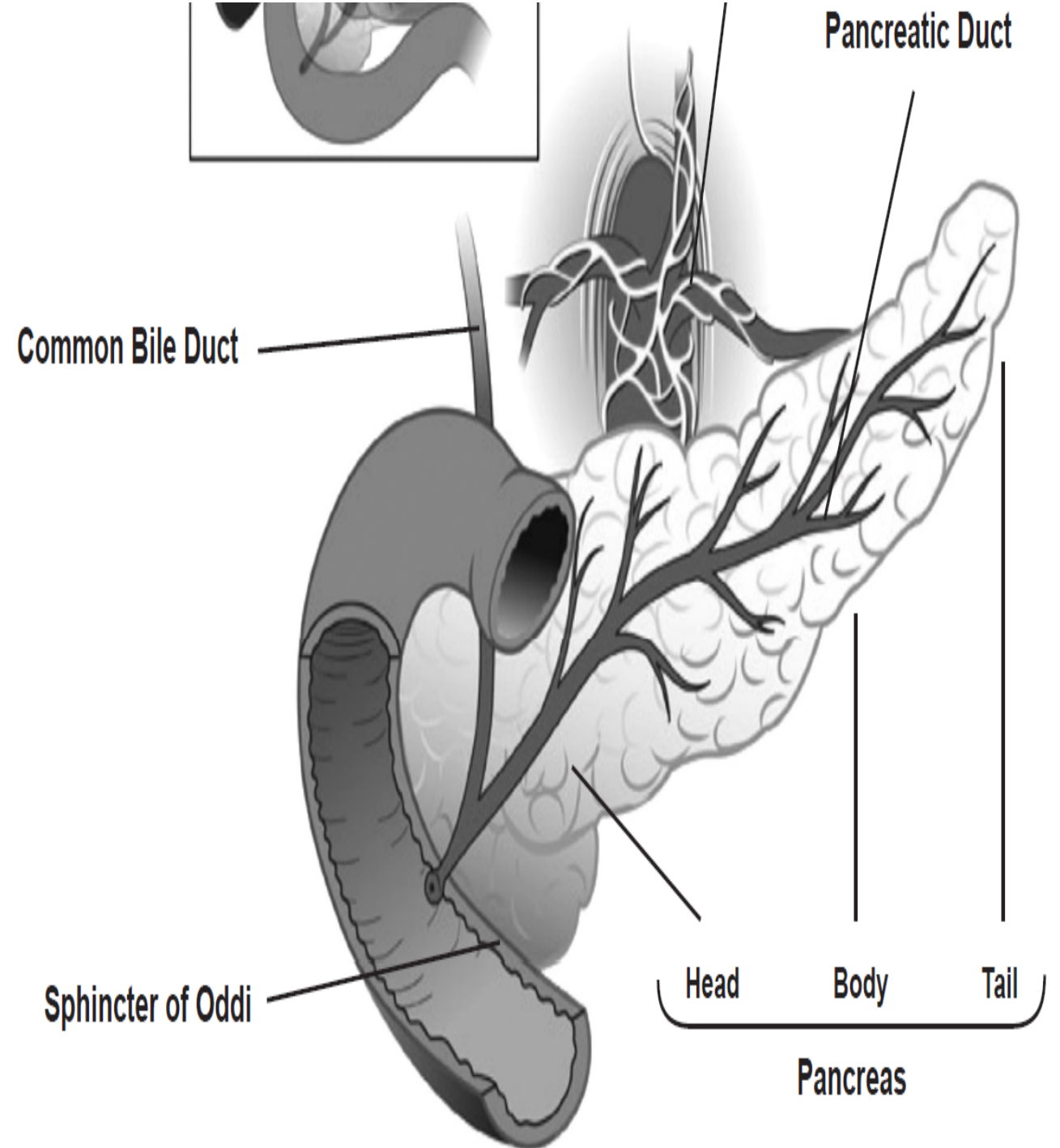
Pancreas

- The pancreas is pear-shaped gland and approximately 6-8 inches long, located between the stomach and the spine.
- Produces enzymes to digest food and secrete insulin hormones that help regulate metabolism.



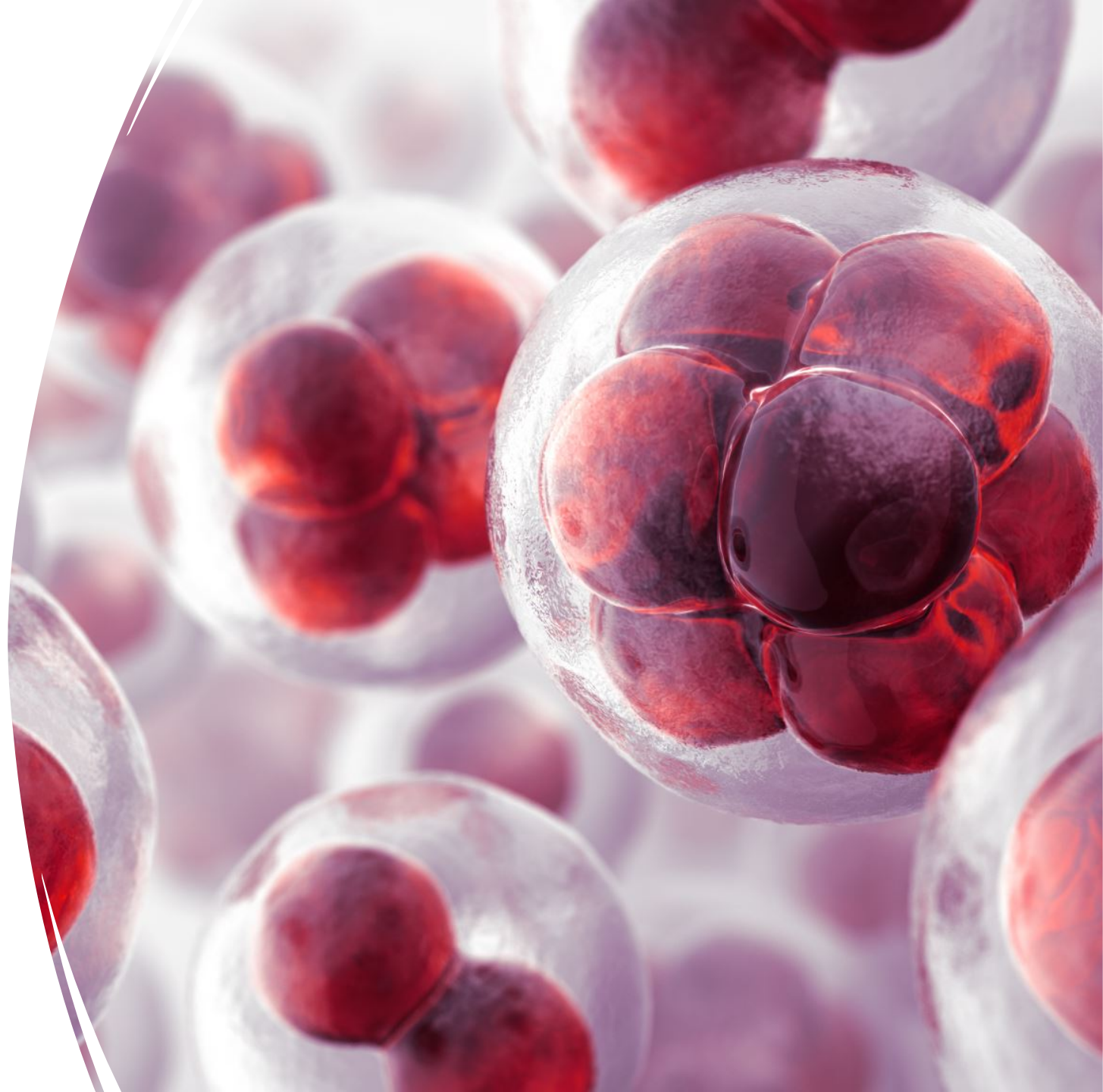
Ducts involved

- The pancreatic duct is a channel that runs through the pancreas and empties digestive juices into the small bowel.
- The common bile duct is another channel that drains bile from the gallbladder and runs through the head of the pancreas.



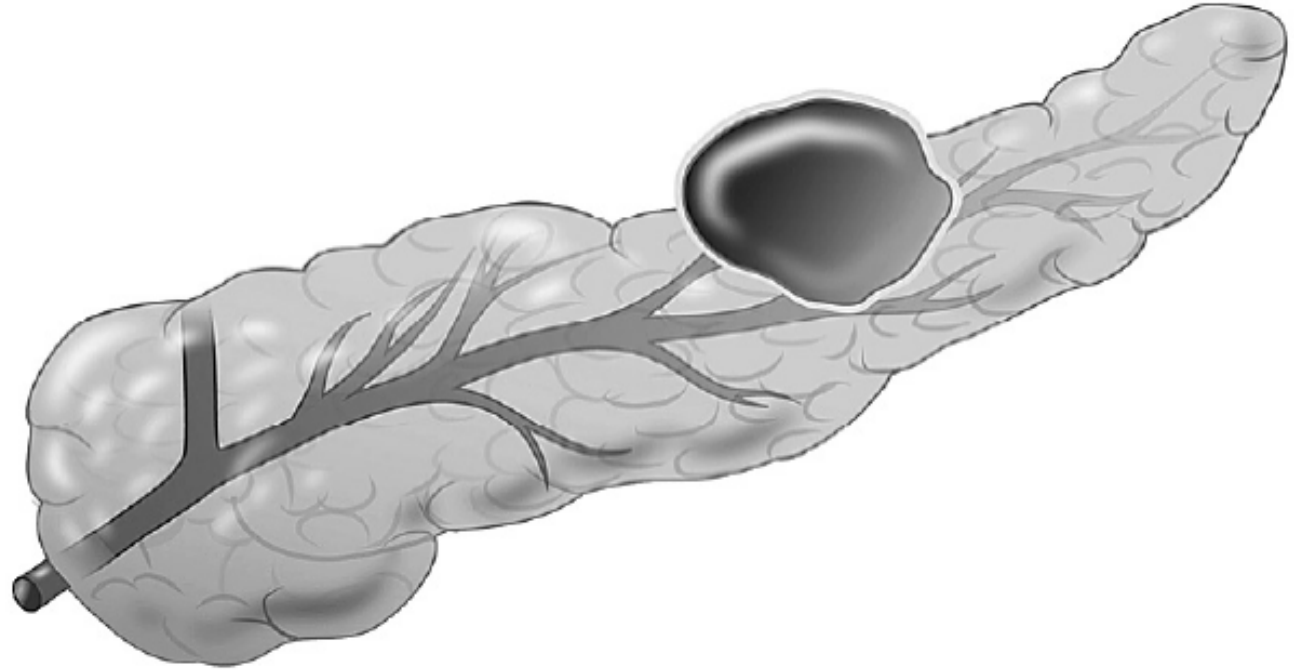
PANCREATIC CYSTS

- Pancreatic cysts are abnormal, sac-like pockets of fluid within pancreas.
- Different types of cysts.

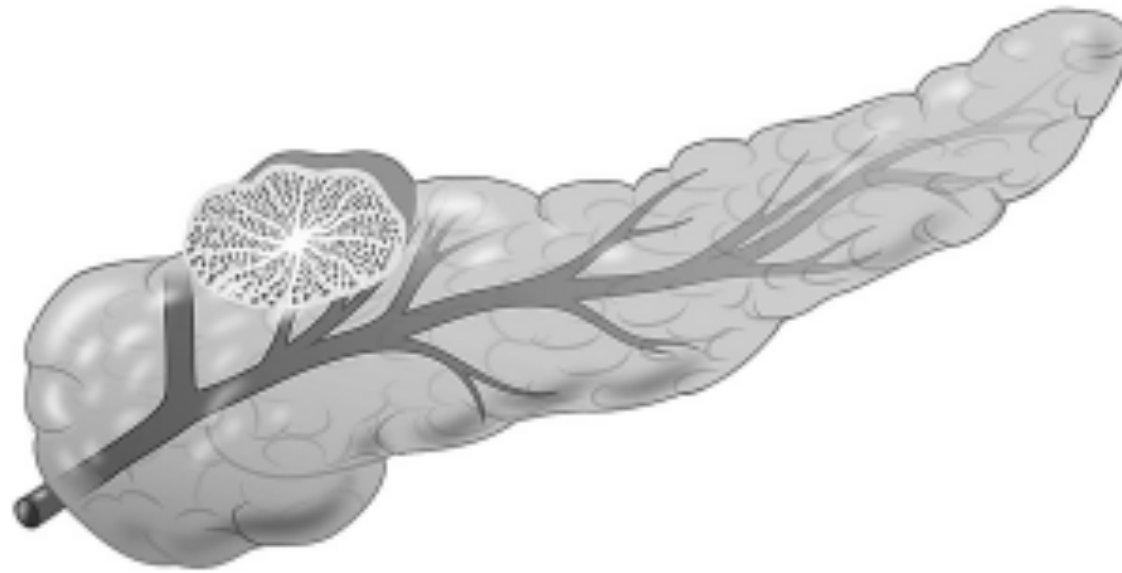

Types of Cysts

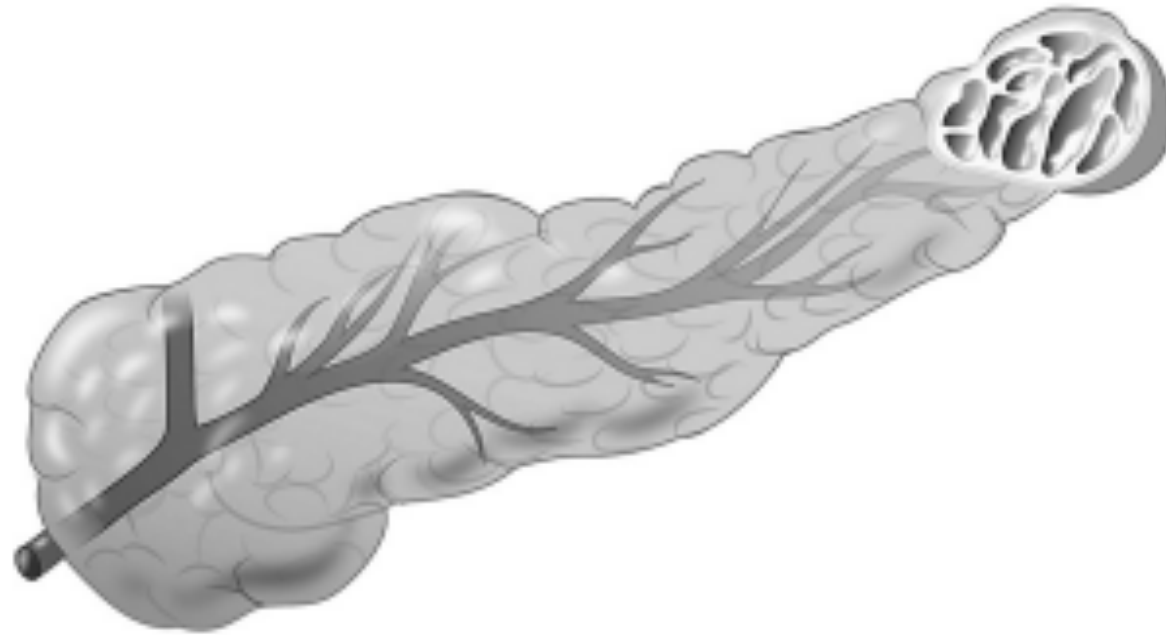Pancreatic Pseudocysts



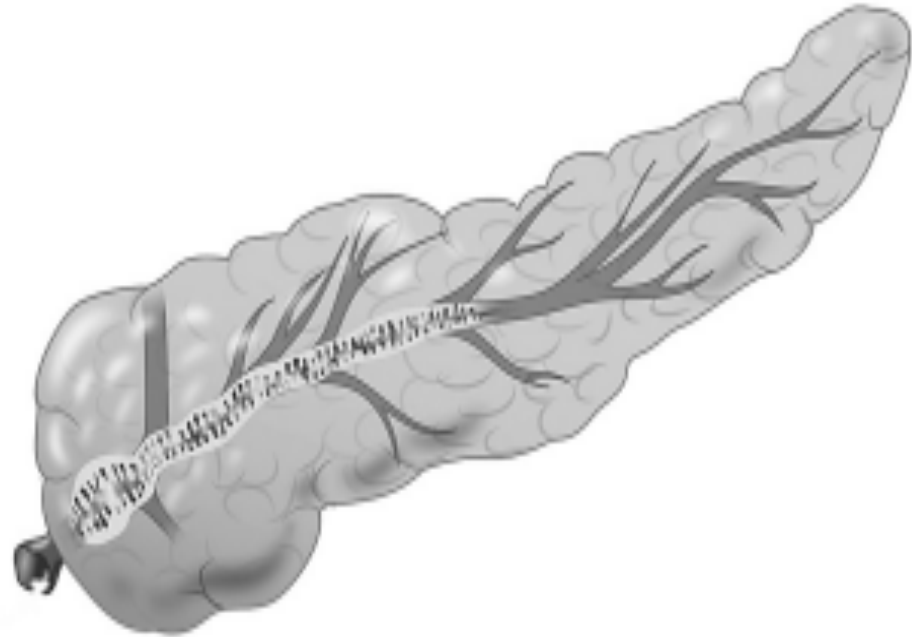
Serous Cystadenomas (SC)



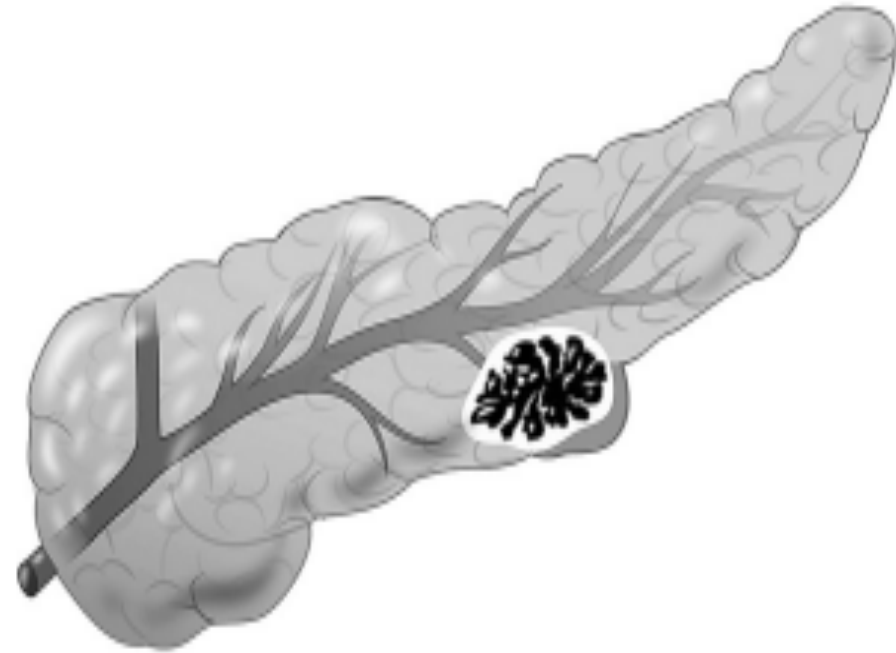
Mucinous Cystic Neoplasm (MCN)



Intraductal
Papillary Mucinous
Neoplasm (IPMN)



Solid
Pseudopapillary
Neoplasm (SPN)



Pancreatic Cysts
types knowledge
check

Survey | Poll Everywhere



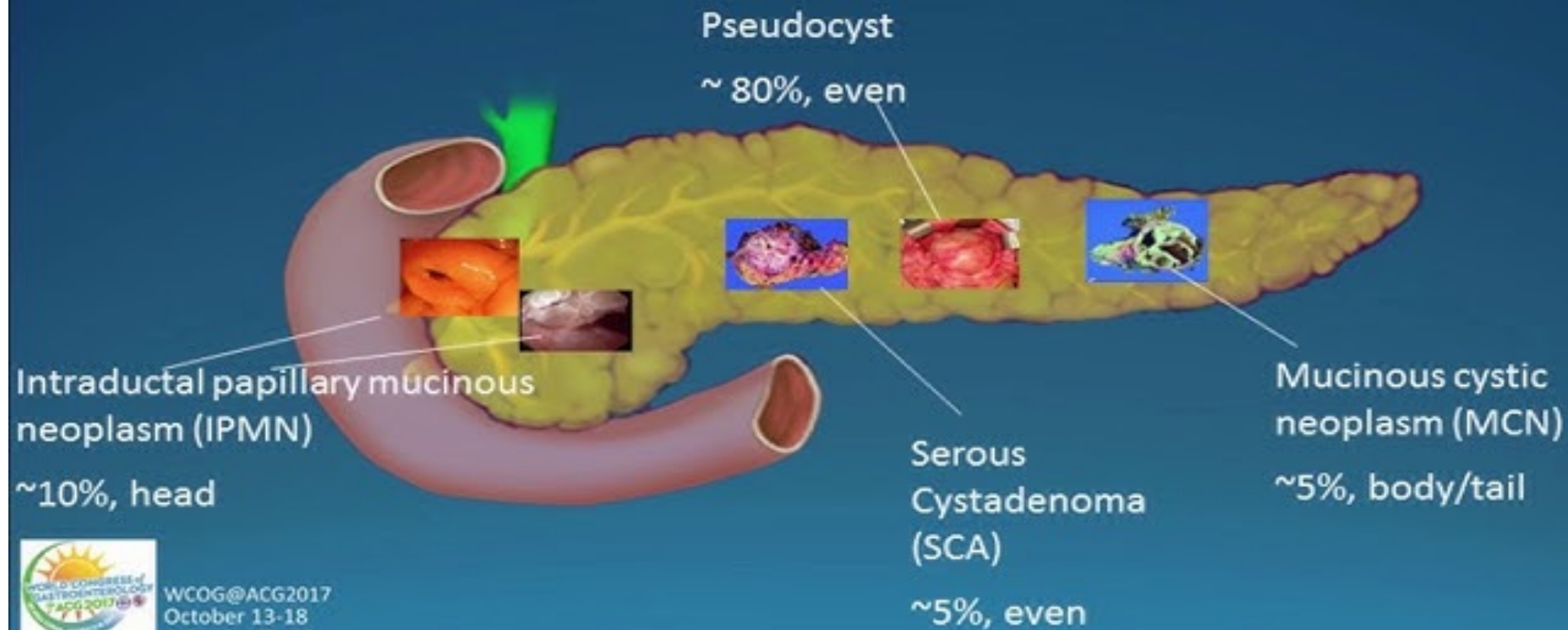
Symptoms of Pancreatic Cysts

Jaundice

Nausea and Vomiting

Upper Abdominal Pain that radiates to the back and shoulders.

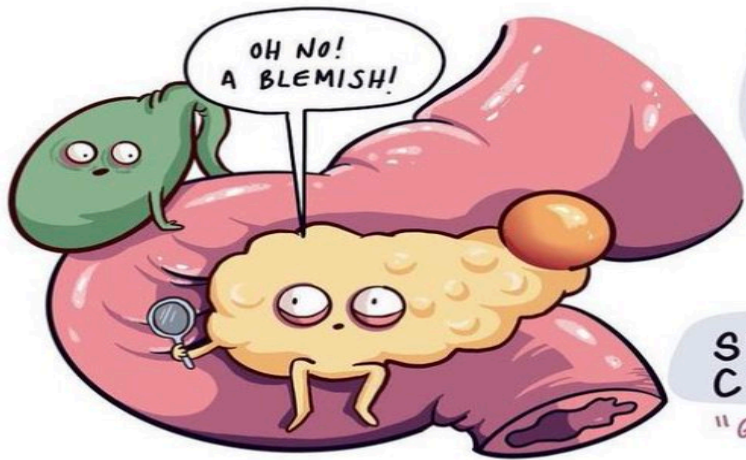
Most Common Cystic Lesions



WCOG@ACG2017
October 13-18
Orlando, Florida

CYSTIC PANCREATIC TUMORS

@maidoodles




SEROUS CYSTADENOMA

"GRANDMOTHER TUMOR"



- occurs in older females
- "bunch of grapes"



INTRADUCTAL PAPILLARY MUCINOUS NEOPLASM

"GRANDFATHER TUMOR"

- occurs in elderly males

SOLID PSEUDO-PAPILLARY NEOPLASM

"DAUGHTER TUMOR"




- occurs in young women & children



MUCINOUS CYSTIC NEOPLASM

"MOTHER TUMOR"

- occurs in middle-aged women



Risk Factors of Pancreatic Cysts

Gall Stones

Alcohol use

Abdominal Injury

Pancreatitis

Von Hippel- Lindau
disease- Genetic
disease affecting
pancreas



Diagnostic tests for Pancreatic Cysts

- Trans abdominal ultrasound
- CT/MRI
- Endoscopic Ultrasonography
- Endoscopic Retrograde Cholangiopancreatography

Tests continued..

Needle Biopsy

Tissue extracted to analyze under a microscope

Used to determine if a mass or lump is cyst , an infection , a benign tumor, or cancer.

Fine needle aspiration/ core needle biopsy.



Tests continued.. Needle Aspiration

Endoscopic ultrasound:

- 19- gauge fine needle aspiration
- Success rate is 97.12%
- Risk of pancreatitis.
- IV sedation
- Biopsy needle through the skin and into the pancreas.
- Sample of fluid/pus from cyst.

What's
next?

Sample of cysts fluid
to determine whether
it has potential to be
malignant or not

Size of the cyst,
location of cyst etc.

Complications
from needle
biopsy/needle
aspiration

Excessive bleeding

Cutting a hole in your small
intestines

Infection

Acute Pancreatitis



Nursing Considerations

Pre-procedure:

- Patient education and consent
- Informed consent
- Assessment- medical history, allergies and coagulation status, medications.
- NPO status
- Administer antibiotics



Nursing Considerations Continued...

During procedure:

- Prevent infection- Aseptic technique, antibiotics.
- Monitoring vital signs and oxygen saturation.
- Observe for signs of discomfort or adverse reactions.
- Provide emotional support.
- Encourage relaxation techniques.

Nursing Considerations Continued....

Post Procedure:

- Monitor Vital signs, signs of bleeding and infection.
- Assess biopsy site for bleeding.
- Administer pain medications as needed.
- Patient comfort
- Education- No heavy lifting and when to expect the results.



Comfort Check

How comfortable you feel about taking care of the patient after endo needle biopsy/ aspiration procedure?

[Survey | Poll Everywhere](#)



Treatment of Pancreatic Cysts

Cyst size and type of cyst

Ability to operate and location of cyst

Presence of symptoms such as pain or weight loss or jaundice

Surgical risks

Malignant potential

Other medical conditions

Surgery

Whipple
procedure

Distal
Pancreatectomy



QUESTIONS?

References

- Barresi, L., Crinò, S. F., Fabbri, C., Attili, F., Poley, J. W., Carrara, S., Tarantino, I., Bernardoni, L., Giovanelli, S., Di Leo, M., Manfrin, E., Tacelli, M., Bruno, M. J., Traina, M., & Larghi, A. (2018). Endoscopic ultrasound-through-the-needle biopsy in pancreatic cystic lesions: A multicenter study. *Digestive endoscopy : official journal of the Japan Gastroenterological Endoscopy Society*, 30(6), 760–770. <https://doi.org/10.1111/den.13197>
- Bartel, M. J., & Raimondo, M. (2017). Endoscopic Management of Pancreatic Cysts. *Digestive diseases and sciences*, 62(7), 1808–1815. <https://doi.org/10.1007/s10620-017-4544-8>
- Al-Haddad, M., El Hajj, I. I., & Eloubeidi, M. A. (2010). Endoscopic ultrasound for the evaluation of cystic lesions of the pancreas. *JOP : Journal of the pancreas*, 11(4), 299–309.
- “Pancreatitis and Pancreatic Cancer.” *SlideShare*, 19 Oct. 2018, <https://www.slideshare.net/AnshuYadav31/pancreatitis-and-pancreatic-cancer>.
- “https://twitter.com/Gio_Marchegiani/status/1722653093198709099.” *X (Formerly Twitter)*, https://twitter.com/Gio_Marchegiani/status/1722653093198709099. Accessed 6 Feb. 2024.
- “Warning Signs of Pancreatic Cancer.” *AARP*, <https://www.aarp.org/health/conditions-treatments/info-2020/advances-in-pancreatic-cancer-treatment.html>. Accessed 6 Feb. 2024.